

ผลการรักษาผู้ป่วยอุบัติเหตุที่ได้รับการปิดช่องท้องชั่วคราว ในโรงพยาบาลสงขลานครินทร์

โกเมศวรรี ทองขาว
 บุรภัทร สังข์ทอง
 โอสรีย์ อัครบวร
 ประรารณา ไชยนิรมล
 ขนิษฐา แก้วแสงเรือง

Outcomes after Temporary Abdominal Closure for Trauma Patients: Experiences from Songklanagarind Trauma Center.

Komet Thongkhao, Burapat Sangthong, Osaree Akaraborworn, Prattana Chainiramol,
 Khanitta Kaewsangrueng

Department of Surgery, Faculty of Medicine, Prince of Songkla University,
 Hat Yai, Songkhla, 90110, Thailand.

E-mail: komet014@hotmail.com

Songkla Med J 2014;32(2):73-81

บทคัดย่อ:

วัตถุประสงค์: เพื่อศึกษาผลการรักษาผู้ป่วยอุบัติเหตุที่ได้รับการปิดช่องท้องแบบชั่วคราวหลังการผ่าตัดช่องท้อง
วัสดุและวิธีการ: ทำการศึกษาแบบย้อนหลังในผู้ป่วยอุบัติเหตุที่มีอายุตั้งแต่ 15 ปีขึ้นไป และได้รับการปิดช่องท้อง
 แบบชั่วคราวหลังการผ่าตัดช่องท้องในโรงพยาบาลสงขลานครินทร์ ระหว่างวันที่ 1 มกราคม พ.ศ. 2550 ถึง 31
 ธันวาคม พ.ศ. 2551 โดยใช้ข้อมูลจากฐานข้อมูลอุบัติเหตุโรงพยาบาลสงขลานครินทร์และเวชระเบียนผู้ป่วย
ผลการศึกษา: ผู้ป่วย 43 รายได้รับการปิดช่องท้องแบบชั่วคราวในช่วงระยะเวลา 2 ปี เป็นเพศชายร้อยละ 80
 อายุเฉลี่ย 35 ปี ค่าเฉลี่ยของระดับความรุนแรงของการบาดเจ็บ (injury severity score) เท่ากับ 29 ผู้ป่วย
 ส่วนใหญ่ได้รับการปิดช่องท้องแบบชั่วคราวเนื่องจากการทำ damage control surgery เทคนิคที่ใช้มากที่สุด
 ในการปิดช่องท้องแบบชั่วคราวคือ vacuum pack technique ระยะเวลาโดยเฉลี่ยที่จำเป็นต้องปิดช่องท้องแบบ

ภาควิชาศัลยศาสตร์ คณะแพทยศาสตร์ มหาวิทยาลัยสงขลานครินทร์ อ.หาดใหญ่ จ.สงขลา 90110

รับต้นฉบับวันที่ 9 พฤษภาคม 2556 รับลงตีพิมพ์วันที่ 1 ธันวาคม 2556

ชั่วคราวเท่ากับ 4 วัน ร้อยละ 40 ของผู้ป่วยสามารถเย็บปิดผนังหน้าท้องได้ ผู้ป่วยร้อยละ 30 เกิดภาวะไส้เลื่อนผนังหน้าท้อง อัตรารอดชีวิตเท่ากับร้อยละ 70

สรุป: ผู้ป่วยส่วนใหญ่ที่ได้รับการปิดช่องท้องแบบชั่วคราวรอดชีวิตและสามารถเย็บปิดผนังหน้าท้องได้ ปัญหาสำคัญในระยะยาวของผู้ป่วยกลุ่มนี้คือการเกิดภาวะไส้เลื่อนผนังหน้าท้องขนาดใหญ่ ซึ่งจำเป็นต้องได้รับการผ่าตัดแก้ไขต่อไป

คำสำคัญ: การปิดช่องท้องแบบชั่วคราว, ผู้ป่วยอุบัติเหตุ, ไส้เลื่อนผนังหน้าท้อง

Abstract:

Objective: Temporary abdominal closure is an acceptable method in the modern care of trauma patients but the optimal technique and strategic care remains unclear. We examine our experiences with these severely injured patients.

Material and Method: A retrospective study was made of all adult (age ≥ 15 years) trauma patients who experienced of temporary abdominal closure from January 2007 to December 2008 at Songklanagarind Hospital, a level I trauma center. Data were retrieved from the trauma registry and medical records.

Results: Forty-three patients met the inclusion criteria. The mean age was 35 years and the average injury severity score was 29. Damage control surgery was the most common situation requiring temporary closure and usually managed with the vacuum pack technique. The average duration of an open abdomen was four days. Primary fascial closure was accomplished in 17 patients (40%). The accepted ventral hernia approach was applied in 13 patients (30%). One patient developed an enteroatmospheric fistula. Thirty patients (70%) survived until discharge.

Conclusion: Most trauma patients requiring temporary abdominal closure survive and subsequent primary fascial closure is achieved in nearly half of them. Early abdominal wall closure reduces fistula formation. The major long-term morbidity is a giant ventral hernia.

Keywords: open abdomen, temporary abdominal closure, trauma patients

Introduction

Temporary abdominal closure after a laparotomy for trauma is reserved for severe trauma patients for whom a relaparotomy is planned,^{1,2} as part of a “damage control” procedure^{3,4} and who are at a high risk of or have developed abdominal

compartment syndrome.⁵⁻⁸ Several techniques for temporary abdominal wound closure have been described.⁹⁻¹⁴ Each technique should provide containment and protect the intra-abdominal organs from mechanical injury and contamination. However, the optimal method of temporary closure, as well

as the morbidity and mortality associated with various techniques, remains unclear. The objectives of this study were to evaluate the indications, fascial closure rate, morbidity and mortality in adult trauma patients who had temporary abdominal closure at Songklanagarind Hospital, a level I trauma center.

Material and Method

The retrospective review was undertaken at Songklanagarind Hospital, a level I trauma center. Songklanagarind Hospital is an eight hundred bed university hospital in southern Thailand. Data on trauma patients who received an emergency laparotomy from January 1, 2007 to December 31, 2008 were retrieved from the trauma registry and medical records. The inclusion criterion was adult (age ≥ 15 years) trauma patients who underwent temporary abdomen closure. We excluded patients who died during their initial operation.

Temporary abdominal closure techniques were defined as (1) a skin only or towel clip closure: all patients who underwent a skin only closure using a running non-absorbable suture or a towel clip placed approximately 1 cm. apart (Figure 1), (2) a Bogota bag: all patients who had a non-adherent, non-absorbable prosthetic material (e.g. the urine bag) sewed to the skin of the laparotomy wound, (3) polyglactin mesh: all patients who had a polyglactin mesh sewed to the rectus sheath then covered by a sterile moist gauze (Figure 2), and (4) vacuum pack (sandwich technique): all patients who had a perforated plastic sheet placed

over the abdominal viscera followed by a sterile moist gauze and two tube drains then covered with iodophor-impregnated polyester drape. The tube drains were connected to wall suction with negative pressure applied at about 80-100 mmHg. (Figure 3).

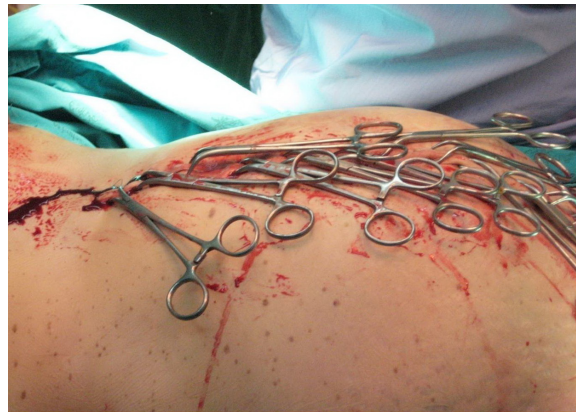

Figure 1 Temporary skin closure by towel clips

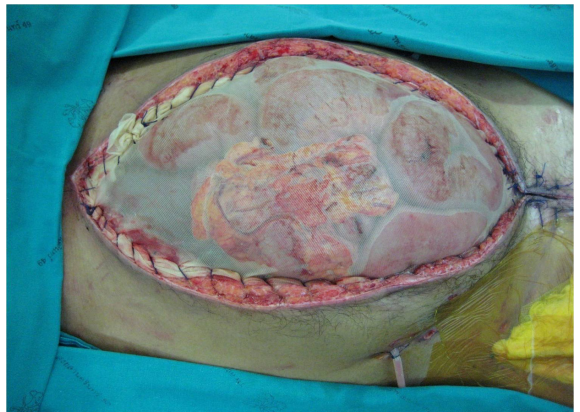


Figure 2 Polyglactin mesh sewed to the rectus sheath

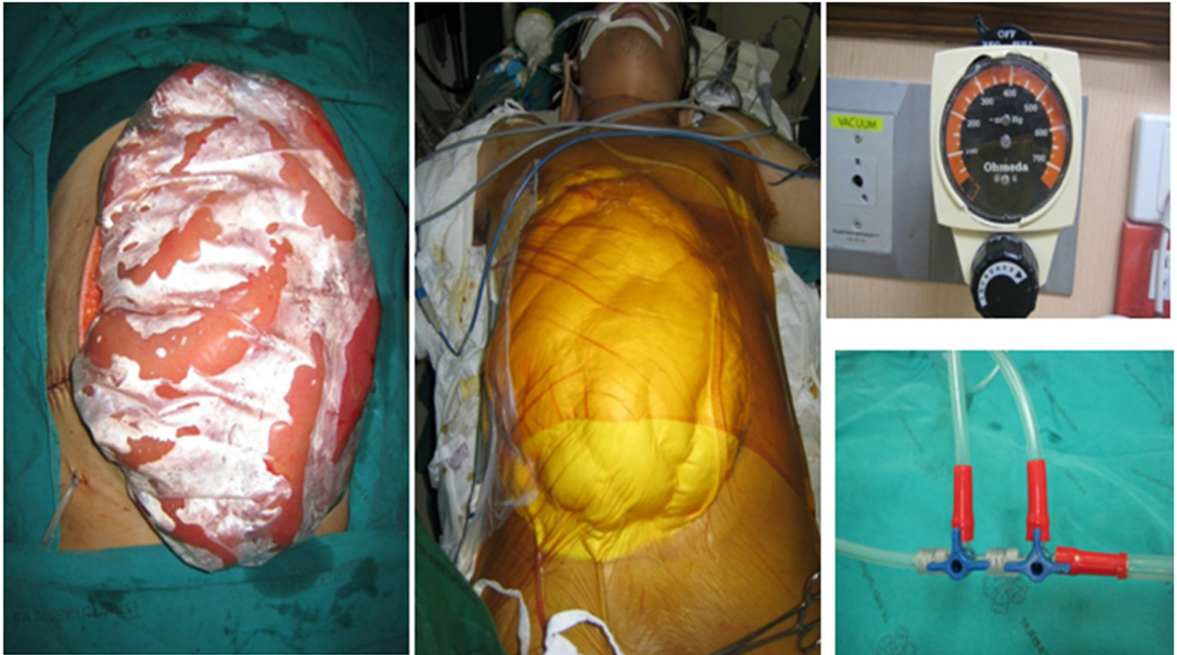

Figure 3 Vacuum pack (sandwich technique) a perforated plastic sheet placed over the abdominal viscera followed by a sterile moist gauze and tube drains then covered with iodophor-impregnated-polyester drape. The tube drains were connected to wall suction

The indication for temporary closure was determined by using the operative note or as stated in the medical records. The indications were classified into four categories: (1) damage control surgery: when the abbreviated procedure was carried out on patients in extremis, followed by stabilization of the patient in the intensive care unit for 24 to 48 hours, then transfer of the patient back to the operating theater for the definitive procedure; (2) planned reoperation: when a second look procedure (e.g., to reassess bowel viability, to change the dressing in a contaminated peritoneal cavity); (3) inability to close: when fascial necrosis or fasciitis had occurred or the surgeon felt fascial closure would involve too much tension; and (4)

abdominal compartment syndrome: when intra-abdominal pressure (trans urinary bladder) ≥ 35 cmH₂O or there was a tense abdomen with increased airway pressure or oliguria.

Definitive abdominal wall closure was classified into two categories: (1) primary fascial closure and (2) planned ventral hernia management using skin closure alone (when fascial closure is too tight and patient's condition precludes repeated operation), bipedicles skin flap closure (when skin closure alone is impossible, bilateral skin flaps were created and combined with relaxing incisions located at the bilateral mid-axillary line) and split thickness skin graft (STSG) placed on the granulation tissue overlying abdominal content or absorbable mesh.

Data collected included patients' demographics, indications and techniques for temporary abdominal closure, techniques for definitive abdominal wall closure, and abdominal complications related to the operation reported descriptively.

This study was carried out in compliance with the regulations for clinical research of the Faculty of Medicine of Prince of Songkla University.

Results

One hundred eighty-six patients required emergency laparotomy during the two-year study period. Forty-three patients met the inclusion criteria and were analyzed. Patient demographics are shown in Table 1.

Table 1 Patient characteristics

Age (years)	35±15
Sex Male:Female	39:4
Mechanism of injury	
Blunt injury	
Motorcycle crash	17 (40%)
Motor vehicle crash	9 (21%)
Pedestrian hit by car	3 (7%)
Penetrating injury	
Gunshot wound	9 (21%)
Stab wound	3 (7%)
Blast bomb injury	2 (5%)
Injury severity score	29±11 (range,16-57)

The initial indications and techniques for temporary abdominal closure versus outcomes are listed in Table 2. Most of the patients required open abdomen management for damage control surgery (65%). The vacuum pack technique was commonly used for temporary closure (93%).

Thirty patients (70%) survived to undergo abdominal wound closure. Seventeen patients (40%) underwent fascial closure within 2.6 days (range, 1 to 5 days). Six patients (14%) underwent skin closure alone and four patients (9%) required the bipedicle skin flap technique to close the abdomen. Three patients (7%) required skin grafting alone to cover the abdomen, one patient underwent split-thickness skin graft after a granulation bed had been achieved through a polyglactin mesh, and the other two patients underwent split-thickness skin graft after a granulation bed had been achieved on the intra-abdominal viscera. The average open abdomen period before definitive abdominal closure was 4 days.

Thirteen patients (30%) died before definitive abdominal closure. The causes of death were exsanguinating hemorrhage (54%), multiple organ failure (31%), and severe brain damage (15%). No patient died after a definitive abdominal closure.

Abdominal complications developed in 20 patients (47%) during initial hospitalization (Table 3). Deep surgical site infection and intra-abdominal collection frequently occurred after temporary abdominal closure followed by reopening of the abdominal wound after closure. Thirteen patients (30%) were discharged alive with planned ventral hernias.

Discussion

The present study emphasizes the continuing challenge for surgeons in providing care to this group of critically injured patients. The management of catastrophic abdominal injuries with temporary abdominal closure, the so-called "open abdomen", has gone through various evolutions.¹⁶ Among

Table 2 Indications and techniques for temporary abdominal closure versus outcomes

	Number of patients (cases)	Survived with fascial closure (cases)	Survived with planned ventral hernia management (cases)	Fascial closure rate (%)	Overall survival (%)
Indication					
Damage control surgery	28	13	6	46.4	67.9
Planned re-operation	6	1	5	16.7	100.0
Inability to close	5	3	1	60.0	80.0
Abdominal compartment syndrome	4	-	1	0.0	25.0
Technique					
Skin only/Towel clips closure	2	2	-	100.0	100.0
Vacuum pack	40	15	12	37.5	67.5
Absorbable mesh	1	-	1	0.0	100.0
Total	43	17	13	39.5	69.8

Table 3 Abdominal complications

	Cases
Deep surgical site infection	11
Intraabdominal collection	11
Relaparotomy after closure	6
Skin necrosis	6
Anastomosis leakage	3
Bowel evisceration	2
Enteroatmospheric fistula	1
Abdominal compartment syndrome	1

the many techniques described, the vacuum pack technique was the most frequently used in this present study. Placement of the perforated plastic sheath over the visceral peritoneum helps contain the viscera and prevents adherence to the abdominal

wall and allows removal of excess peritoneal fluid. A surgical towel or gauze placed over the plastic sheath as an absorptive layer provides support to the vacuum pack once suction is applied. Tube drains were placed on the surgical towel or gauze and covered with an adhesive, iodophor-impregnated polyester drape and then connected to a wall suction at 80–100 mmHg continuous negative pressure. Other techniques for temporary closure of the abdominal wall such as using absorbable synthetic mesh, towel-clip closure and skin closure alone were applied rarely in this study.

An absorbable mesh sewn to the fascia to form a fascial bridge was one of the earliest attempts to create a tension-free temporary abdominal closure.¹⁷ While preventing lateral retraction of the musculo-fascial layer and allowing for two or three reopening

without requiring replacement, it is absorbed over three to four weeks and results in a giant defect for later reconstruction. Moreover, intestinal fistula from desiccation of the intestine under absorbable mesh can still happen¹². In an open abdomen, this enterocutaneous fistula is intractable and often lethal, because it is very difficult to control and repair.

The towel-clip closure and skin closure alone are fast and effective for closing the abdominal wall, but they do not allow sufficient abdominal expansion to avoid intra-abdominal hypertension and abdominal compartment syndrome. A number of studies have reported abdominal compartment syndrome occurs in 13 to 36 percent of patients who require damage control surgery, when skin closure alone or towel clip closure is performed.^{6,9,18} These techniques have been abandoned and supplanted by the vacuum pack technique in our current surgical practice.

The majority of critically ill trauma patients requiring temporary abdominal closure in this study survived. Among the survivors from these catastrophic abdominal injuries, however, two opposing processes do take place and deserve mention. An edematous bowel from massive resuscitation gradually subsides and offers the possibility of re-approximation of the abdominal wall. At the same time, the musculo-fascial edges start to retract laterally and enlarge the musculo-fascial defect. Also, many series have documented a fascial closure rate of only 22 to 70 percent in damage control surgery¹⁹, which possibly reflects a restrictive approach of leaving a laparotomy wound open at the initial operation only when it is definitely unavoidable.

Approximately one-fourth of the patients receiving primary fascial closure in our study suffered from fascial necrosis and septic dehiscence. Excessive tension from a desperate closure of the abdomen in the face of intestinal contamination from the initial insult was reasonably responsible for these complications and similar to other previous reports.^{20,21} This serious local complication frequently requires extensive debridement of the abdominal wall and left the patients with a larger gap in the fascia. Repeated attempts to approximate the musculo-fascial edges were not always feasible or appropriate, especially in the presence of associated multiple organ dysfunction syndrome or sepsis. Moreover, an unprotected bowel is prone to desiccation, iatrogenic trauma and fistula formation.

We preferred prompt coverage of the bowel followed with late abdominal reconstruction typically six to twelve months from the initial operation, the so-called "planned ventral hernia". Many strategies for early intestinal coverage, once it becomes clear that definitive musculo-fascial closure is not possible, have been proposed. The traditional one was covering the open abdomen with an absorbable mesh sewn to the musculo-fascial edges to prevent further lateral retraction of the abdominal wall. Over the course of two to three weeks, once granulation tissue fully develops on the abdominal viscera, skin grafting is performed.^{12,17} We believe that this strategy still takes a long time and are concerned that prolonged granulation on these wounds would contribute to intestinal wall breakdown. We attempted to serially close the abdominal skin over the top and bottom of the laparotomy wound every 24 to 48 hours.

With this approach we normally achieve total bowel coverage with endogenous tissue sometimes with bipedicle skin flaps within one week. We believe this approach has indeed resulted in a lower likelihood of intestinal fistulization over the open abdomen as it appeared in only two percent in this present study. Though this could be considered a success, this group of “planned ventral hernia” accounted for nearly one-third (30%) of the survivors and will require complex abdominal wall reconstruction six to twelve months later.

Conclusion

Most trauma patients requiring temporary abdominal closure survive. Subsequent primary fascial closure is achieved in nearly a half of them. Early abdominal wall closure can reduce fistula formation. A better strategic management is necessary to maximize the number of patients undergoing early primary fascial closure in this challenging condition.

References

- Burch JM, Ortiz VB, Richardson RJ, et al. Abbreviated laparotomy and planned reoperation for critically injured patients. *Ann Surg* 1992; 215: 476 - 83.
- Hirshberg A, Mattox KL. Planned reoperation for severe trauma. *Ann Surg* 1995; 222: 3 - 8.
- Pachter HL, Spencer FC, Hofstetter SR, et al. Significant trends in the treatment of hepatic trauma. Experience with 411 injuries. *Ann Surg* 1992; 215: 492 - 502.
- Sharp KW, Locicero RJ. Abdominal packing for surgically uncontrollable hemorrhage. *Ann Surg* 1992; 215: 467 - 75.
- Ertel W, Oberholzer A, Platz A, et al. Incidence and clinical pattern of the abdominal compartment syndrome after “damage-control” laparotomy in 311 patients with severe abdominal and/or pelvic trauma. *Crit Care Med* 2000; 28: 1747 - 53.
- Offner PJ, de Souza AL, Moore EE, et al. Avoidance of abdominal compartment syndrome in damage-control laparotomy after trauma. *Arch Surg* 2001; 136: 676 - 81.
- Cheatham ML, Malbrain ML, Kirkpatrick A, et al. Results from the international conference of experts on intra-abdominal hypertension and abdominal compartment syndrome. II. Recommendations. *Intensive Care Med* 2007; 33: 951 - 62.
- Deenichin GP. Abdominal compartment syndrome. *Surg Today* 2008; 38: 5 - 19.
- Tremblay LN, Feliciano DV, Schmidt J, et al. Skin only or silo closure in the critically ill patient with an open abdomen. *Am J Surg* 2001; 182: 670 - 5.
- Barker DE, Kaufman HJ, Smith LA, et al. Vacuum pack technique of temporary abdominal closure: a 7-year experience with 112 patients. *J Trauma* 2000; 48: 201 - 7.
- Miller PR, Meredith JW, Johnson JC, et al. Prospective evaluation of vacuum-assisted fascial closure after open abdomen. Planned ventral hernia rate is substantially reduced. *Ann Surg* 2004; 239: 608 - 16.
- Sriussadaporn S, Sriussadaporn S, Pak-art R, et al. Planned ventral hernia with absorbable mesh: a life-saving method in relaparotomy for septic abdomen. *J Med Assoc Thai* 2010; 93: 449 - 56.
- Tsiotos GG, Luque-de León E, Söreide JA, et al. Management of necrotizing pancreatitis by repeated operative necrosectomy using a zipper technique. *Am J Surg* 1998; 179: 91 - 8.
- Tieu BH, Cho SD, Luem N, et al. The use of the Wittmann patch facilitates a high rate of fascial closure in severely injured trauma patients and critically ill emergency surgery patients. *J Trauma* 2008; 65: 865 - 70.
- Rutherford EJ, Skeete DA, Brasel KJ. Management of the patient with an open abdomen: technique in temporary and definitive closure. *Curr Probl Surg* 2004; 41: 815 - 76.

16. Diaz JJ Jr, Cullinane DC, Dutton WD, et al. The management of the open abdomen in trauma and emergency general surgery: part 1-damage control. *J Trauma* 2010; 68: 1425 - 38.
17. Fabian T, Croce MA, Pritchard FE, et al. Planned ventral hernia staged management for acute abdominal wall defects. *Ann Surg* 1994; 219: 643 - 53.
18. Raeburn CD, Moore EE, Biffl WL, et al. The abdominal compartment syndrome is a morbid complication of postinjury damage control surgery. *Am J Surg* 2001; 182: 542 - 6.
19. Boele van Hensbroek P, Wind J, Dijkgraaf MG, et al. Temporary closure of the open abdomen: a systematic review on delayed primary fascial closure in patients with an open abdomen. *World J Surg* 2009; 33: 199 - 207.
20. Miller RS, Morris JA Jr, Diaz JJ Jr, et al. Complications after 344 damage-control open celiotomies. *J Trauma* 2005; 59: 1365 - 74.
21. Barker DE, Green JM, Maxwell RA, et al. Experience with vacuum-pack temporary abdominal wound closure in 258 trauma and general and vascular surgical patients. *J Am Coll Surg* 2007; 204: 784 - 93.