

## Surgical repair of traumatic femoral arteriovenous fistula: report of a case series

อภิรักษ์ เชษฐเผ่าพันธ์<sup>1</sup>  
เจริญเกียรติ ฤกษ์เกลี้ยง<sup>1</sup>  
ประเสริฐ วศินานุกร<sup>2</sup>

### Abstract:

Surgical repair of traumatic femoral arteriovenous fistula: report of a case series

Chetpaophan A, Rergkliang C, Vasinanukorn P.

Department of surgery, Faculty of Medicine,

Prince of Songkla University, Hat Yai, Songkla, 90110, Thailand

Songkla Med J 2004;22(1):55-59

*We report on three patients who developed late complications following a penetrating wound of the lower extremities, in which angiographic findings demonstrated an uncommon pseudoaneurysm and large arteriovenous fistula (>10 mm) of the femoral artery. Surgical reconstructions were performed by various techniques, depending on the fistular size and structural change of the femoral artery. Options of surgical technique included lateral suture, patch arterioplasty, autogenous graft, and prosthetic graft interposition. This report presents various techniques of surgical correction for definitive treatment and good results.*

**Key words:** arteriovenous fistula, surgical technique

---

<sup>1</sup>M.D., Lecturer <sup>2</sup>M.D., Assist. Prof., Department of Surgery, Faculty of Medicine, Prince of Songkla University, Hat Yai, Songkhla, 90110, Thailand

รับต้นฉบับวันที่ 7 มีนาคม 2546 รั้บลงตีพิมพ์วันที่ 5 มกราคม 2547

## บทคัดย่อ:

ผู้รายงานและคณะ ได้รายงานผู้ป่วย 3 ราย ซึ่งเกิดรูรั่วติดต่อทางหลอดเลือดแดงและดำอันเป็นภาวะแทรกซ้อนภายหลังการบาดเจ็บจากบาดแผลถูกยิงบริเวณขาส่วนต้น ซึ่งพบได้ไม่บ่อย โดยผลการฉีดสารทึบแสงหลอดเลือดพบว่าหลอดเลือดแดงและดำบริเวณขาส่วนต้นมีรูรั่วติดต่อกันขนาดใหญ่รวมถึงการโป่งพองของหลอดเลือดแดง การผ่าตัดซ่อมแซมหลอดเลือดแดงและดำที่ติดต่อกันนั้นมีหลายวิธี โดยขึ้นอยู่กับขนาดของรูรั่วและโครงสร้างที่เปลี่ยนไปของหลอดเลือดขาข้างที่เกิดพยาธิสภาพ เทคนิคการซ่อมแซมหลอดเลือดประกอบด้วยการเย็บปิดรูรั่วโดยตรง, การเย็บโดยใช้หลอดเลือดดำปิดด้านข้าง, การใช้หลอดเลือดดำตัดต่อ, รวมถึงการใช้หลอดเลือดเทียมต่อแทนที่หลอดเลือดบริเวณขาส่วนต้น ซึ่งรายงานฉบับนี้แสดงถึงเทคนิคต่างๆ ในการผ่าตัด รวมถึงผลการผ่าตัดที่ได้ผลดี

คำสำคัญ: รูรั่วติดต่อหลอดเลือดแดงและดำ, การผ่าตัด

## Introduction

Arteriovenous fistula (AVF) is an abnormal communication between the arterial and venous system. Arterial injury resulting in a pseudoaneurysm and arteriovenous fistula formation is becoming more frequent together with an increasing incidence of trauma in connection with social violence.<sup>1</sup> The difficulties in detecting vascular injury associated with penetrating trauma of the limb are greater than generally appreciated.<sup>2</sup> Any delay in diagnosis will compromise management and potentially may lead to late sequelae.<sup>3</sup> Traumatic arteriovenous fistula produces several profound pathophysiological and structural changes in the affected vessel wall.<sup>4</sup> We report uncommon large traumatic arteriovenous fistulas (>10 mm in diameter) with delayed presentation, late sequelae, and various surgical corrections.

## Case reports

### Case One

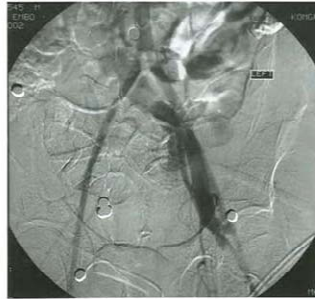
An 18-year-old man sustained a gun shot wound injury at lower abdomen and left thigh six months earlier. Exploratory laparotomy was performed to stop bleeding and for intestinal repair. The AVF was not identified until recently when the patient complained the left leg claudication and chronic swelling. Initial physical examination showed a palpable thrill over the left groin. Angiography (Figure 1A) confirmed a pseudoaneurysm arising from the left common femoral artery and demonstrated a communication with the femoral vein, 8

mm in fistular size. Before surgery, we attempted to embolize the fistular site with coil but were unsuccessful.

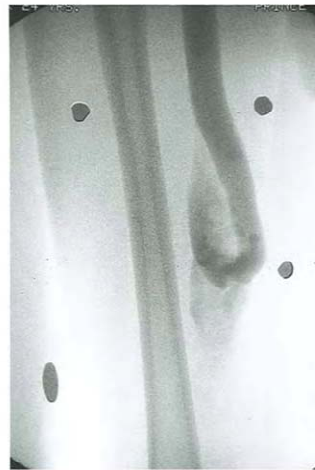Exploration of the left groin revealed a pseudoaneurysm originating from the common femoral artery and an 8-mm-diameter arteriovenous fistula communicating with femoral vein (Figure 2). After proximal and distal control of both artery and vein, separation of the fistula was done. Vein patch arterioplasty was performed at the arterial site. Then, the venous site was closed by lateral femoral venorrhaphy. The patient recovered well and physical examination was entirely normal a month later.

### Case Two

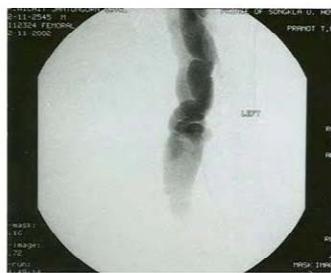A 24-year-old man presented with history of gun shot wound injury at right thigh two years earlier and chronic leg wound for 3 months. Physical examination showed a thrill over the scar at the right mid thigh. The angiography (Figure 1B) demonstrated a pseudoaneurysm and high-flow AVF of 13 mm in diameter at the right superficial femoral artery. Intraoperative examination revealed a 1.5-cm pseudoaneurysm and fistula site at the mid part of the superficial femoral artery. The pseudoaneurysm was excised, interposition of the superficial femoral artery was performed using saphenous vein graft (Figure 3) because of a wide gap at the anastomotic site and marked thinness of the residual arterial wall. The femoral vein was repaired by lateral suture. There were no postoperative complications. The patient completely recovered one month postoperatively.



A



B



C

Figure 1 Femoral angiography demonstrated early filling of the contrast into femoral vein representing AVFs. Case 1 (A), Case 2 (B), Case 3 (C)



A

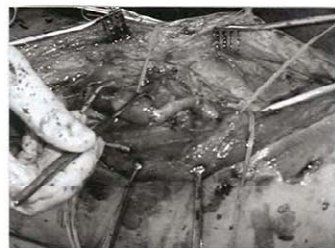

B

Figure 2 Intraoperative finding before (A) and after (B) reconstruction of femoral arteriovenous fistula by vein patch arterioplasty (Case 1)



A



B

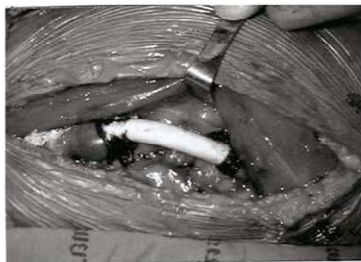Figure 3 Intraoperative finding before (A) and after (B) reconstruction of femoral arteriovenous fistula by saphenous vein graft interposition (Case 2)

Case Three

A 53-year-old man sustained a gun shot wound injury in his left thigh twenty years earlier. The patient complained swelling, chronic wound, and claudication of left leg. Physical examination suspected AVF at the left femoral artery, which was confirmed by angiography (Figure 1C) which showed an AVF at the superficial femoral artery, 12 mm in size, and a pseudoaneurysm. Surgical correction was performed by excision of the pseudoaneurysm, and lateral suture at the femoral vein. A prosthetic graft (polytetrafluoroethylene) was used to interpose between both ends of the superficial femoral artery (Figure 4) because of the discrepancy in size of proximal and distal arteries. Marked improvement of the left leg wound followed the procedure and the thrill disappeared. One month later, a follow up showed healed left leg wound.



A



B

Figure 4 Intraoperative finding before (A) and after (B) reconstruction of femoral arteriovenous fistula by prosthetic graft interposition (Case 3)

Discussion

Since the treatment of traumatic AVFs should be undertaken as soon as possible, recognition of symptoms, definition of clinical signs, and a correct diagnosis are very important.<sup>3,5</sup> It is important for clinicians to be aware of this disorder because early diagnosis and treatment can prevent long-term sequelae.<sup>3,6</sup> Thrill and bruit are typical clinical signs for AVF in both chronic and acute settings. Even without other diagnostic tools, the presence of thrill and bruit over the injury site should alert the clinician to consider AVF existence. In contrast, a pulse deficit should not be considered as a reliable clinical sign of vascular injury or AVF formation.<sup>7</sup> In our report, all patients presented with delayed diagnosis and late sequelae. Our findings in all patients without pulse deficit are similar to the other reports.<sup>3,6,7,11</sup>

Angiography is a reliable diagnostic tool in localizing the site and the size of AVF, and also in the visualization of changes in the contributing vessels.<sup>8</sup> The localization of the fistula is important in view of the surgical procedure and angiographic data are important to determine surgical incision, proximal-distal control vessels, and techniques of surgical correction.<sup>9</sup> In this report, all lesions were demonstrated before the surgical repair. We suggest angiography as the first-line investigation.

Surgical treatment of traumatic AVFs in the lower extremity is controversial, varying from lateral suture, a vein patch angioplasty, end-to-end anastomosis, a vein graft interposition, and prosthetic graft.<sup>10,11</sup> In this report, three techniques were demonstrated and chosen on the basis of vascular pathology (size of vessels) and fistular size. The vein patch arterioplasty was carried out because of the small defect with normal and healthy arterial wall. When the large defect (>10 mm) with discrepancy in size of proximal and distal arteries were identified, a prosthetic graft interposition was performed.

In our opinion, a high index of suspicion, regular reexaminations, and the selective angiography are all important for effective management of AVF resulting from penetrating injury of lower extremities. The type of AVFs reconstructions depend on native arterial size, diameter of fistula, and discrepancy of arterial segment. Endovascular procedures will most likely become the future treatment of choice for

AVFs in various locations, especially coil embolization or covered stent-graft repair.<sup>12</sup> In our report, embolization at fistula site was attempted in one case before surgical reconstruction. The unsuccessful radiological intervention may be due to large fistula size and the discrepancy in size between the arterial segment proximal and distal to the AVF.

### Conclusion

**The traumatic arteriovenous fistula of lower extremity requires immediate surgical treatment to prevent local and systemic complications. Major arteries and veins should be reconstructed. In chronic large AVFs, the appropriate surgical technique for reconstruction should be considered depending on the fistular size and structural change of the femoral artery.**

### References

1. Kollmeyer KR, Hunt JL, Ellman BA, Fry WJ. Acute and chronic traumatic arteriovenous fistulae in civilians. Epidemiology and treatment. *Arch Surg* 1981;116:682-97.
2. Graham AN, Barros D'Sa AA. Missed arteriovenous fistulae and false aneurysms in penetrating lower limb trauma: relarning old lessons. *Injury* 1991;22:179-82.
3. Yilmaz AT, Arslan M, Demirkilic U, Ozal E, Kuralay E, Tatar H, et al. Missed arterial injuries in military patients. *Am J Surg* 1997;173:110-4.
4. Stigall KE, Dorsey JS. Late complications of traumatic arteriovenous fistula. Case report and overview. *Am J Surg* 1989;55:180-3.
5. Khoury G, Sfeir R, Nabbout G, Jabbour-Khoury S, Fahl M. Traumatic arteriovenous fistulae: "The Lebanese war experience". *Eur J Vasc Surg* 1994;8:171-3.
6. Seaton DL. Traumatic arteriovenous fistula of the leg. An easily missed diagnosis. *J Fam Pract* 1998;46:247-50.
7. Rich NM, Hobson RW, Collins GJ. Traumatic arteriovenous fistulas and false aneurysms: a review of 558 lesions. *Surgery* 1975;78:817-28.
8. McDonald EJ, Goodman PC, Winestock DP. The clinical indications for arteriography in trauma to the extremity. *Radiology* 1975;116:45-47.
9. Sirinek KR, Gaskill HV, Dittman WI, Levine BA. Exclusion angiography for patients with possible vascular injuries of the extremities: a better use of trauma center resources. *Surgery* 1983;94:598-603.
10. Rich NM. Vascular trauma. *Surg Clin North Am* 1973;53:1367-92.
11. Robbs JV, Carrim AA, Kadwa AM, Mars M. Traumatic arteriovenous fistula: experience with 202 patients. *Br J Surg* 1994;81:1296-9.
12. Marin ML, Veith FJ, Panetta TF, Cynamon J, Barone H, Schonholz C, et al. Percutaneous transfemoral insertion of a stented graft to repair a traumatic femoral arteriovenous fistula. *J Vasc Surg* 1993;18:299-304.